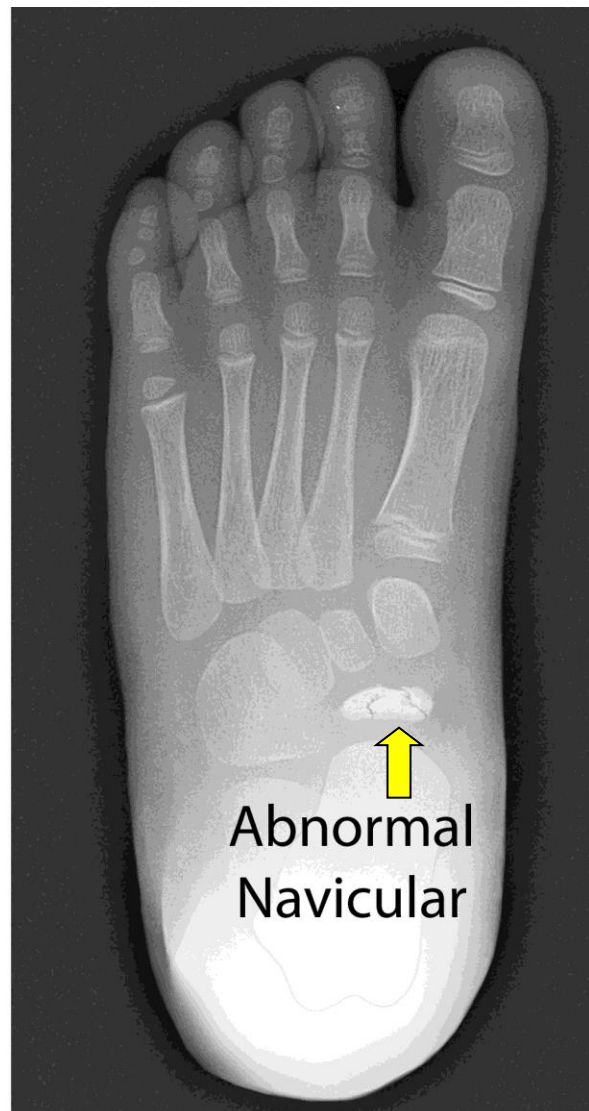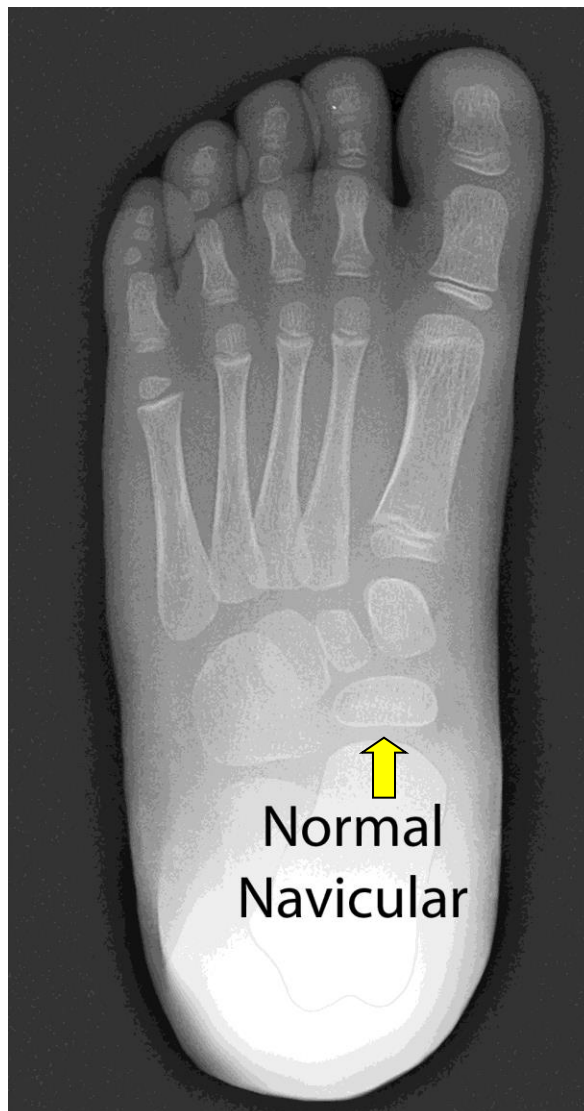


# KOHLER DISEASE

Kohler disease is a rare, painful bone disorder of a child's midfoot most commonly seen between two and nine years of age. It was first described in 1908 by Dr. A. Kohler, a radiologist, who noted in children with complaints of foot pain characteristic x-rays findings of marked increased density (whiteness) and irregularity in the growth and development of a bone in the foot (navicular bone). Kohler disease affects males five times more often than females. Typically, just one foot is affected.



No absolute reason for this condition has been found. Some orthopedic specialists believe that Kohler disease may be linked to a injury in the area of the navicular bone. Biopsies of the area have suggested that the blood supply to the bone may be affected by the weight bearing pressures and stresses caused by repeated running, jumping, hopping, and skipping.

Most children with Kohler disease present to the office with a limp and may walk on the outside border of the foot to relieve pressure on the arch area. There can be pain, swelling, redness or warmth on the top of the foot. The diagnosis is confirmed by x-ray and physical examination.

Symptoms can last for a few days or may persist for up to two years. Most children appear to grow out of the disorder and the affected bones regain their size, density and structure within a year.

Treatment is designed to realize the pain and diminish a limp if present. Most children improve with restriction of their activities and the use of anti-inflammatory medications such as Ibuprofen. Others may require temporary immobilization in a removable brace/boot. Occasionally cast treatment is recommended for children with prolonged, severe symptoms. Surgery is not indicated in the treatment of Kohler disease.

Kohler disease is a benign, self-limiting condition that does not lead to residual deformity or disability in adulthood



©John T. Killian, M.D. & Sharon Mayberry, M.D.